

Hip joint impingement

Weight-Bearing Upright MRI Images

MEDSERENA Upright MRI Centre

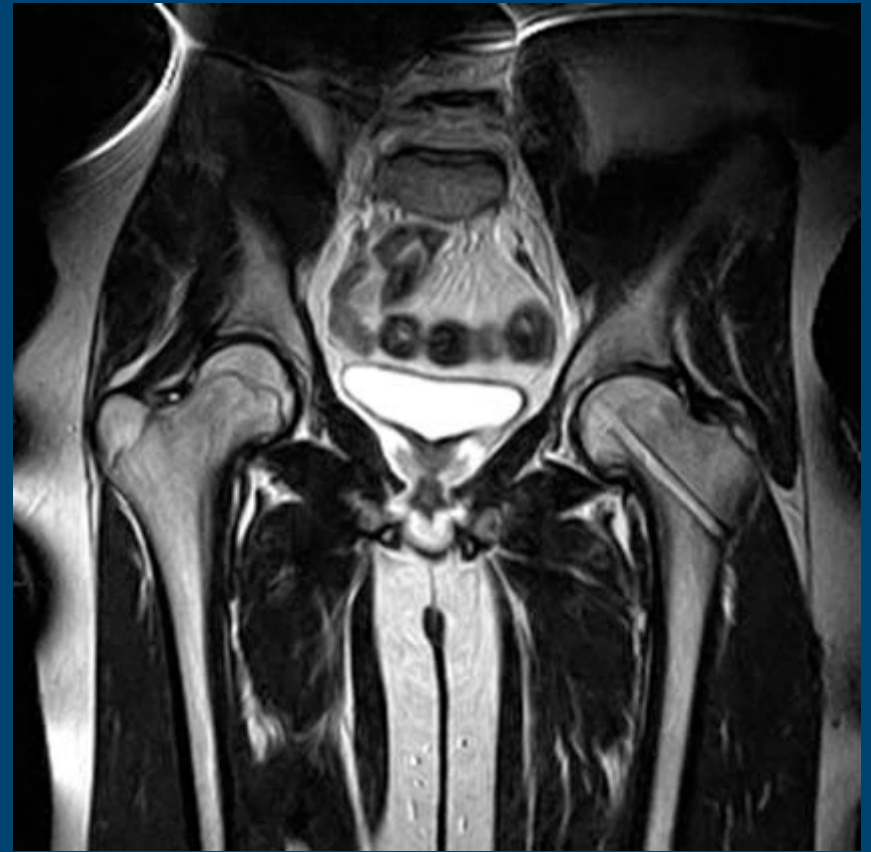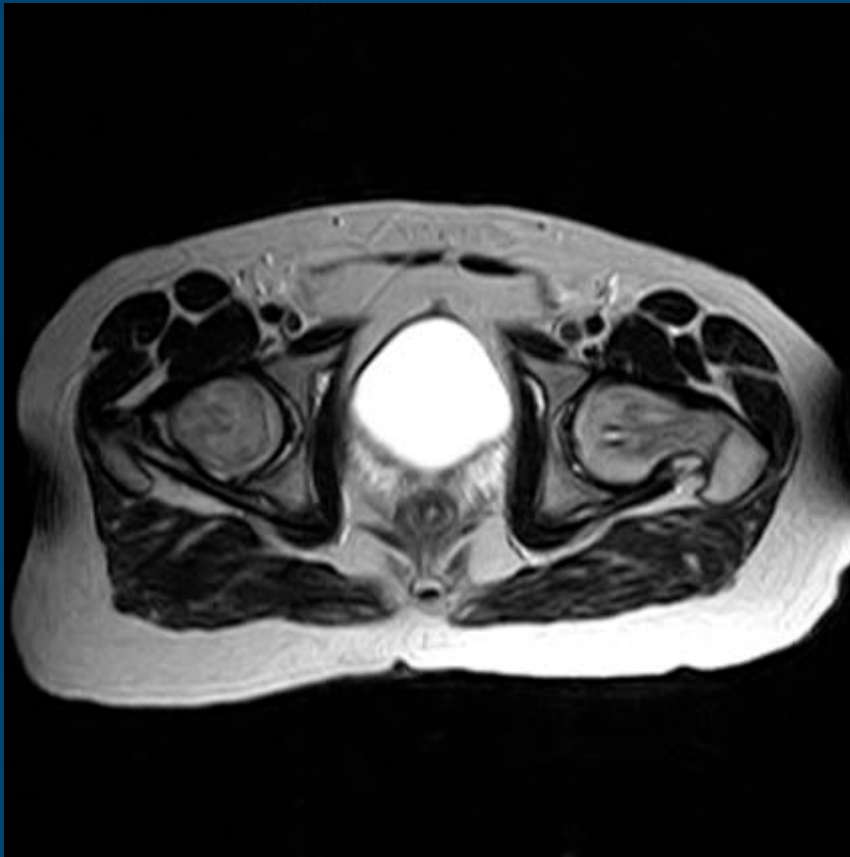
114a Cromwell Road | Kensington | London SW7 4ES

Tel: 020 7370 6003 | Fax: 020 7373 0339 | Web: www.trulyopenmri.com

Painful Left hip

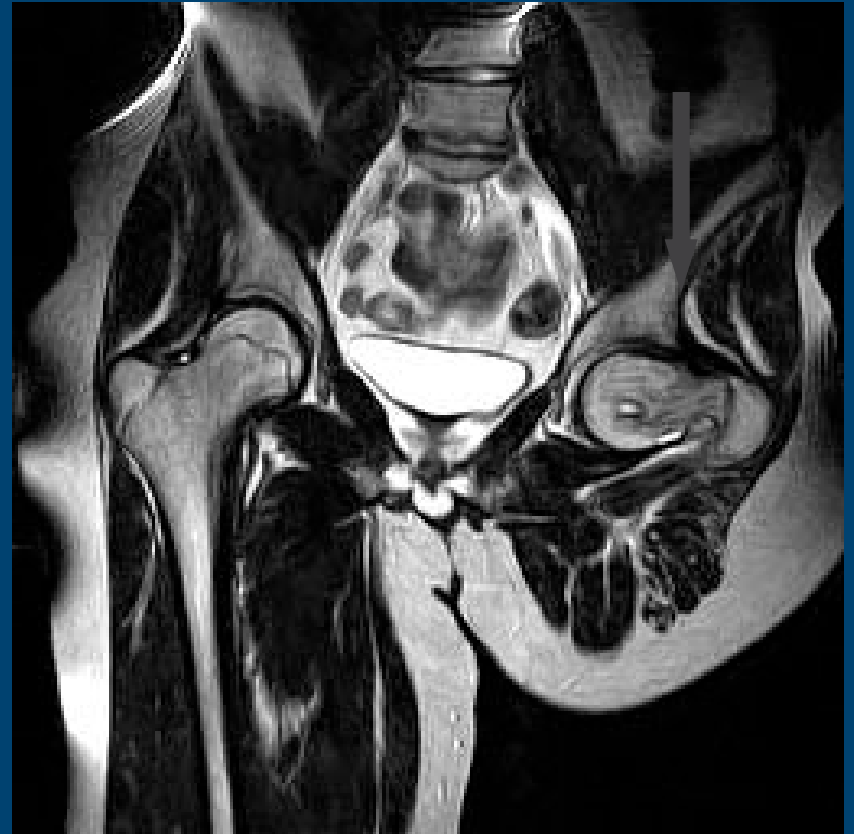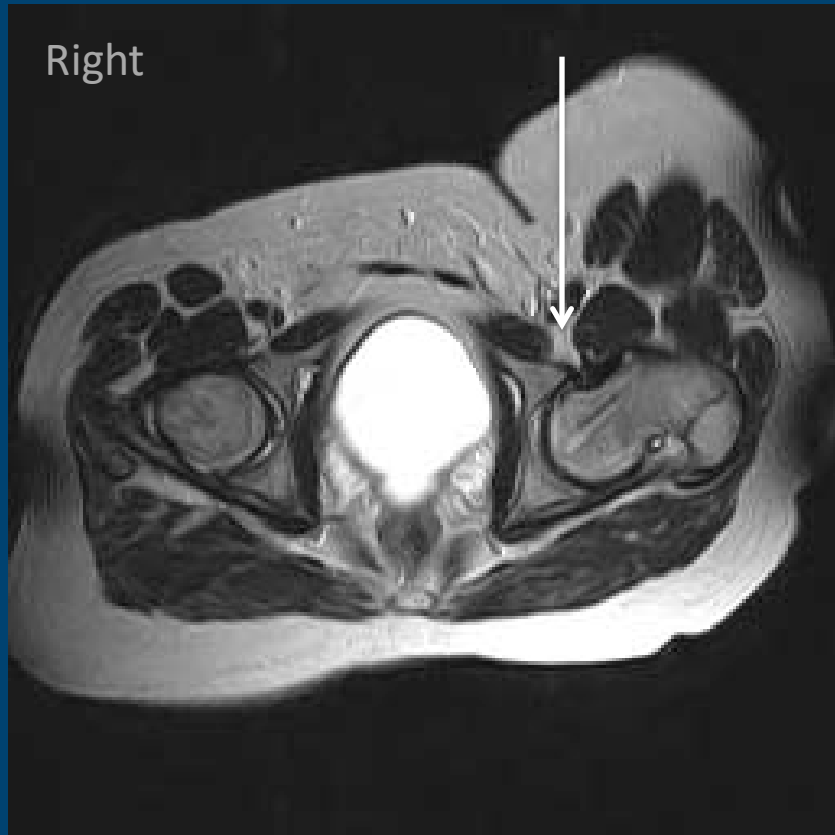17 year old boy with treated left SUFE

Now complains of painful clicking left hip



Standing on both legs

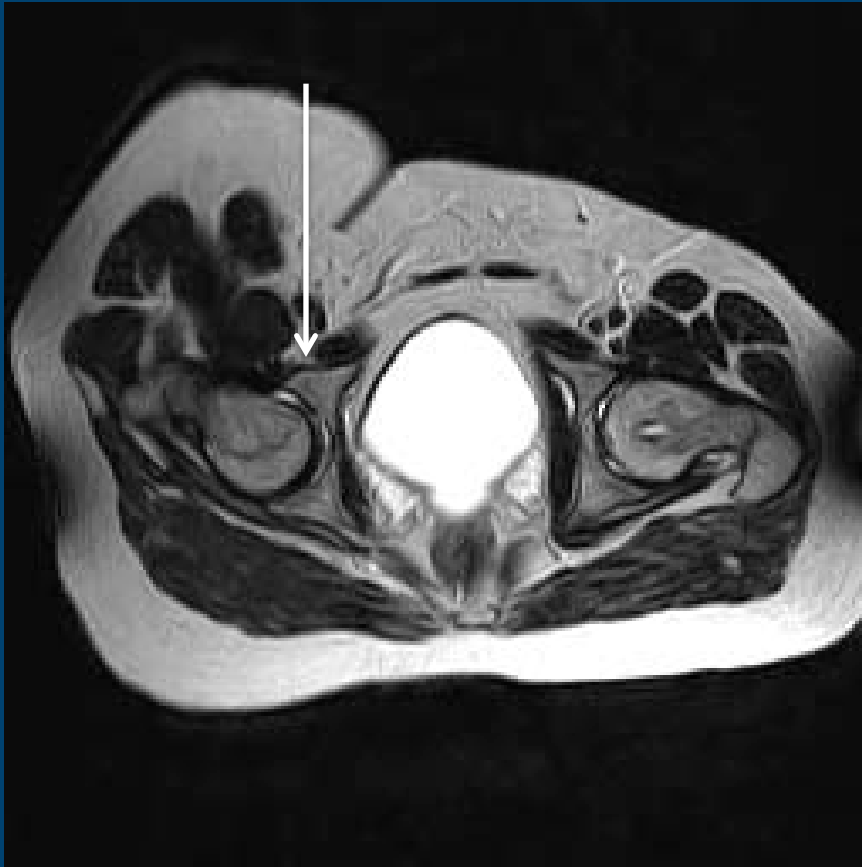Painful Left hip



Flexed left hip i.e. Standing right leg

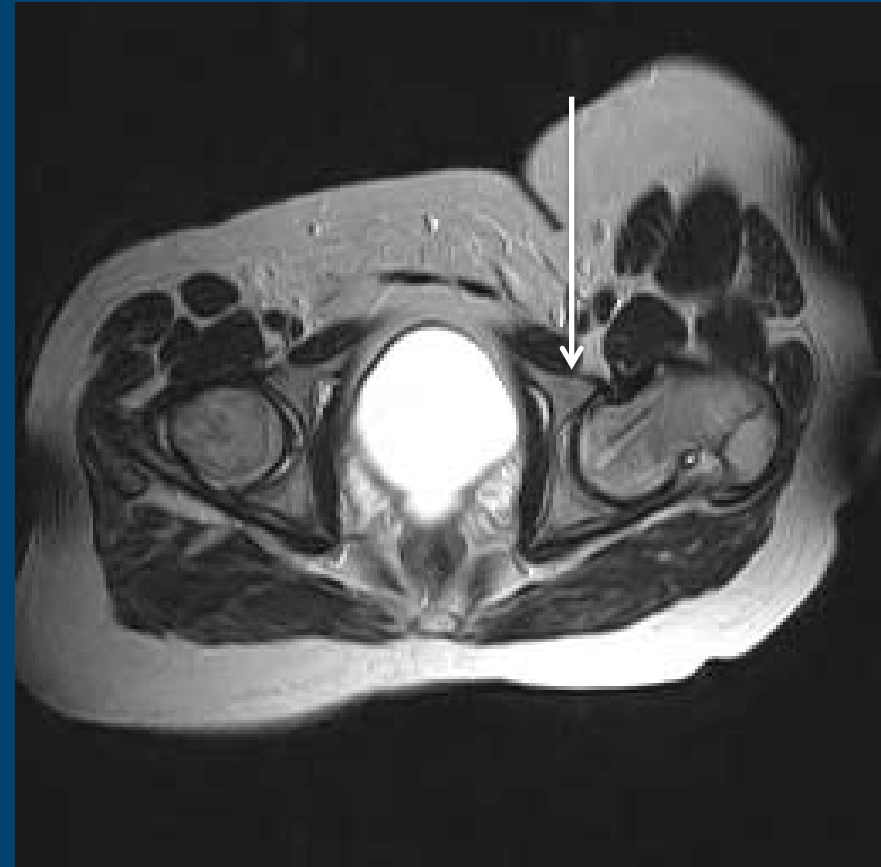Cam impingement (White arrow)

Painful Left hip



Flexed asymptomatic right hip

No impingement (White arrow)



Flexed left hip

Impingement (White arrow)

Treatment – Arthroscopic debridement of the anterior labrum